

## TRANSPORT OF *EIMERIA NECATRIX* SPOROZOITES IN THE CHICKEN: EFFECTS OF IRRITANTS INJECTED INTRAPERITONEALLY

M. A. Al-Attar\* and M. A. Fernando

Department of Pathology, University of Guelph, Guelph, Ontario, Canada N1G 2W1

**ABSTRACT:** Light and electron microscopic observations confirmed that *Eimeria necatrix* sporozoites first enter villous epithelial cells of the chicken small intestine and are transported to the crypts by mononuclear cells. Ultrastructurally, these cells resemble granulated intraepithelial lymphocytes (IEL) rather than macrophages, as suggested previously. The injection of chickens intraperitoneally (i.p.) with a variety of irritants, including proteose peptone, at the time of oocyst inoculation or up to 12 hr postinoculation (PI) resulted in a delay in the arrival of sporozoites at the crypt. Significantly fewer sporozoites had arrived at the crypt by 24 hr PI in i.p.-injected birds as compared to controls. This delay in the arrival of sporozoites at the crypts was reflected by a delay in the development of intestinal lesions and in peak oocyst production. However, there was no significant decrease in the total numbers of oocysts produced by these birds as compared to controls, indicating that no significant loss of sporozoites occurs during the possible rerouting of the parasites.

The presence of infective stages in extraintestinal sites was detected by transferring various tissues to coccidia-free recipients. Infection was transferable by gut, liver, and spleen from irritant-injected and control birds at all time intervals studied (12, 24, 36, and 48 hr PI). Infection was also transferable with blood and kidney, but not consistently. A small number of oocysts was passed by the recipients of peritoneal wash from irritant-injected birds at 12 hr PI. In all transfers, the prepatent period was normal, suggesting that the migrant stages are sporozoites.

First-generation meronts of the coccidia, *Eimeria acervulina*, *E. maxima*, *E. mitis*, *E. necatrix*, and *E. tenella* develop in crypt epithelial cells of the chicken gut. Light microscopic observations by several authors indicate that the sporozoites of *E. acervulina*, *E. necatrix*, and *E. tenella* first enter surface epithelial cells and are transported to the crypts via the lamina propria by cells resembling macrophages (Van Doorinck and Becker, 1957; Challey and Burns, 1959; Patillo, 1959; Doran, 1966). More recently, Lawn and Rose (1982) confirmed that *E. tenella* sporozoites first enter surface enterocytes but presented ultrastructural evidence to show that host cells transporting the sporozoites from surface to crypt epithelium are not macrophages but resemble those designated as granulated intraepithelial lymphocytes. The intraepithelial lymphocyte has also been implicated as the host cell in which the first-generation meront of the turkey coccidium *E. dispersa* develops to maturity (Millard and Lawn, 1982).

In experiments described here, we confirm that the sporozoites of *E. necatrix* are transported from villous to crypt epithelial cells by host mononuclear cells that resemble, ultrastructural-

ly, the granulated intraepithelial leukocytes described by Lawn and Rose (1982). We also show that the injection of an irritant substance intraperitoneally into chickens at the time of oocyst inoculation causes a delay in the arrival of the sporozoites at the crypt. Initially, these intraperitoneal irritants were used for a different purpose detailed below. Intestinal lesions in *E. necatrix*-infected chickens occur during the development of second-generation meronts, 3-6 days postinoculation of oocysts. Stockdale and Fernando (1975) found heavy heterophil infiltration of the infected areas of the gut during the development of second-generation meronts and suggested that these cells may be partly responsible for the lesions. In preliminary experiments we tried to modify the lesions by redirecting heterophils into the peritoneal cavity with irritant injections as described by Trifonov et al. (1977). However, we report in this paper that irritants given intraperitoneally did not alter the intestinal lesions seen 5 days postinoculation, but instead interfered with the early part of the life cycle, i.e., the arrival of sporozoites at the crypt. This led us to investigate further the effects of intraperitoneally injected irritants on the transport of sporozoites including the possibility that they are carried by host cells to extraintestinal sites. The presence of sporozoites in various tissues was detected by the ability of these tissues to induce infections in coccidia-free recipient chickens.

Received 10 July 1986; revised 24 November 1986; accepted 25 November 1986.

\* Present address: Department of Pathology and Forensic Medicine, College of Veterinary Medicine, University of Baghdad, Al-Ameria, Iraq.



## MATERIALS AND METHODS

White leghorn chickens, 4–10 wk of age, were used in all experiments. They were reared coccidia-free and provided drug-free food and water *ad libitum*.

The Guelph strain of *Eimeria necatrix* was used for inoculating chickens and the oocyst cultures were less than 4 wk old at the time of inoculation. Chickens were inoculated with sporulated oocysts by intubation of the crop.

### Histological examination

For counting sporozoites in histological sections, intestines were placed in Bouin's fixative, and longitudinal pieces, approximately  $1 \times 0.3$  cm, were embedded in methacrylate. Two- $\mu$ m-thick sections were stained with hematoxylin and acid fuchsin as described by Peirce (1980). From each intestine 3 pieces were routinely processed for counting, 1 each from the following areas: A, immediately distal to the duodenum; B, halfway between the duodenum and Meckel's diverticulum; and C, immediately above Meckel's diverticulum.

For all other purposes intestines were fixed in 10% formalin in 0.1 M phosphate buffer, pH 7.4, and paraffin sections (5  $\mu$ m thick) were stained with hematoxylin and eosin.

For electron microscopy, a piece of intestine 1 cm square from area B, as described above, was pinned onto a flat piece of rubber, washed free of debris with cold phosphate-buffered saline, pH 7.2 (PBS), and immersed in cold (4°C) fixative containing 2% glutaraldehyde and 2.5% paraformaldehyde in 0.1 M phosphate buffer, pH 7.2. After approximately 15 min, the fixed tissue was removed from the rubber, cut into pieces 1–2 mm square, and placed in fresh fixative. Selected pieces of tissue were postfixed in 1% osmium tetroxide in phosphate buffer, dehydrated, and embedded in Spurr's resin. One- $\mu$ m-thick sections were stained with methylene blue for light microscopic evaluation. For electron microscopy, gold or silver sections were stained with uranyl acetate and lead citrate.

### Irritants injected intraperitoneally

The effectiveness of several substances was explored for this purpose. Proteose peptone and thioglycollate broth were used as soluble nonparticulate irritants and 2% hydrolysed starch and 1% Sephadex G75 (Pharmacia) were the particulate irritant substances used (Long and Rose, 1976). Ten percent proteose peptone (Difco Laboratories) in 0.9% NaCl was sterilized in an autoclave prior to use (Trifonov et al., 1977). Depending on their age and size, each bird received 7–12 ml of oocysts intraperitoneally (i.p.) at various times postinoculation (PI) as indicated.

### Lesion scores

The severity of gross intestinal lesions was scored on an ascending scale from 1–5 in birds killed 5 days PI: 1 = Presence of meront nests, seen as white foci from the serosal surface, and/or petechial hemorrhages; 2 = 1 + congestion and/or thickening of intestinal wall; 3 = 2 + ecchymotic hemorrhage in mucosa; 4 = 3 + fibrin and mucous exudate in lumen; 5 = 4 + blood clots and/or casts in lumen.

## Statistics

Where indicated, Student's *t*-test was used for statistical analyses of significance and  $P < 0.05$  was regarded as significant.

### Preparation of donor tissues for transfer to recipient birds

Blood, peritoneal washings, mucosa from the small intestine, and liver, spleen, and kidneys from donors were transferred to uninfected recipients by oral inoculation via the crop. Blood was withdrawn from the donor birds before they were killed and the various organs and tissues processed, as indicated below, for transfer.

**Blood:** Ten milliliters of blood was withdrawn by heart puncture into a syringe containing heparin such that the final concentration in the blood sample was 10 IU/ml. This blood was inoculated orally via the crop into a recipient bird.

**Peritoneal wash:** The peritoneal cavity was washed twice with 10-ml portions of PBS containing 2–4 IU of heparin per ml. The washes were combined and centrifuged at 500 *g* for 10 min. The pellet was resuspended in 2 ml PBS and inoculated orally into a recipient bird.

**Gut:** The mucosa of the small intestine, from the end of the duodenum to Meckel's diverticulum, was scraped with a glass microscope slide, suspended in 5–10 ml PBS by passing several times through an 18-gauge needle attached to a syringe, and inoculated orally into a recipient bird.

**Liver:** The gallbladder was removed and the whole liver homogenized in PBS using a blade-type homogenizer (Omnimixer). The homogenate was brought up to a total volume of 40 ml and 5 ml of this homogenate was inoculated orally into a recipient bird.

**Spleen:** The spleen was homogenized in 2–5 ml PBS in a Dounce tissue grinder with a loose-fitting pestle and inoculated orally into a recipient bird.

**Kidneys:** The kidneys were similarly homogenized in 5–10 ml of PBS and inoculated orally into a recipient bird.

### Design of experiments

The effects of several irritants injected intraperitoneally on the severity of the intestinal lesions (as indicated by lesion scores), development of meronts, transport of sporozoites from villous to crypt epithelium and to extraintestinal sites, and on oocyst production were investigated in birds inoculated with sporulated oocysts. Birds inoculated with oocysts per os, and given 1 or more irritant injections intraperitoneally, will be referred to as irritant-injected birds and birds inoculated per os at the same time and with similar doses of oocysts but not given any intraperitoneal irritant injections will be referred to as control birds.

**Lesion scores:** Three experiments were performed to determine the effect of irritants given i.p. on the intestinal lesions in *E. necatrix*-infected birds as judged by lesion scores. In experiment 1, 12 chickens were each inoculated with  $1.4 \times 10^5$  sporulated oocysts and divided into 2 groups. The 7 chickens in group 1 served as irritant-injected birds and were each given 10 ml proteose peptone i.p. at the time of inoculation and at



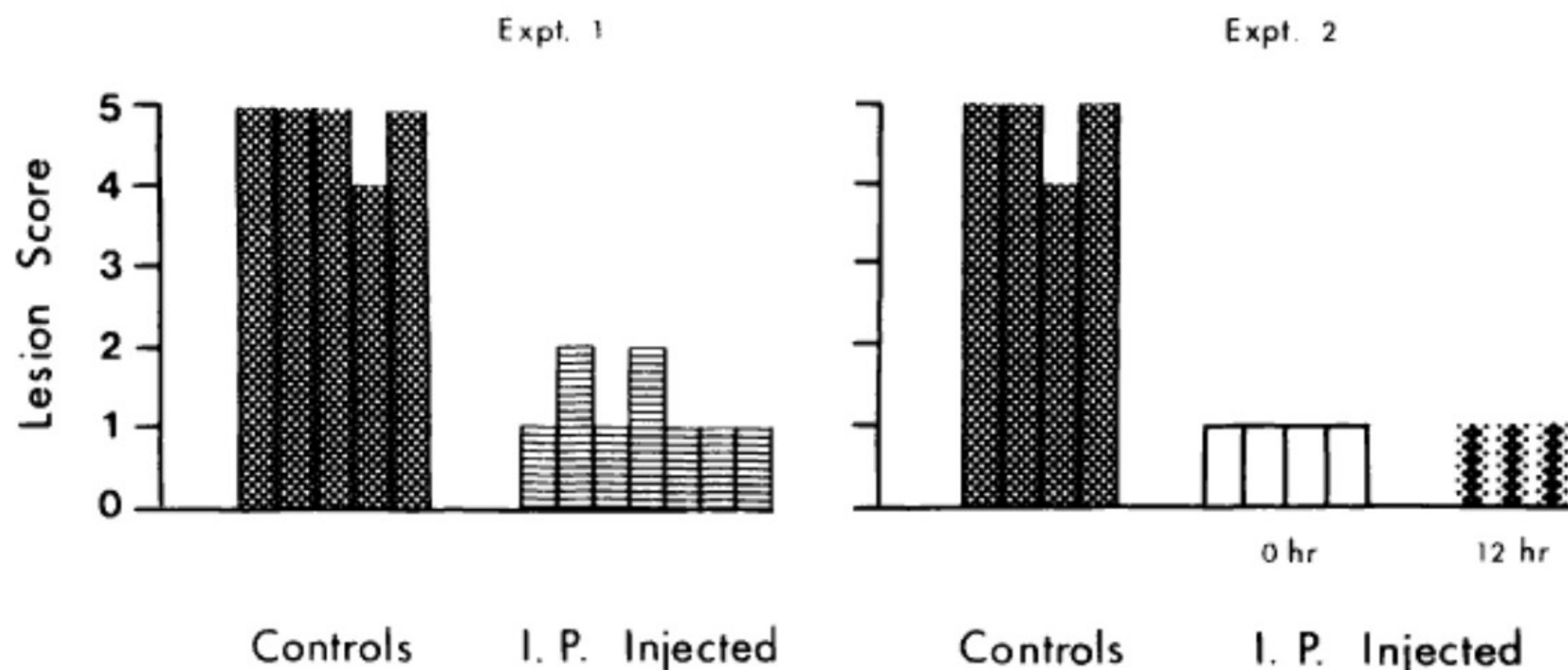


FIGURE 1. Lesion scores of chickens injected intraperitoneally with proteose peptone and those of controls. Each bar represents 1 chicken. In experiment 1, each chicken received i.p. injections of proteose peptone at 0, 24, 48, 72, and 96 hr PI. In experiment 2, chickens in one group received an i.p. injection at 0 hr PI and those in the other group at 12 hr PI (1 chicken in this group died 2 days PI of an unrelated cause). All chickens were inoculated with  $1.4 \times 10^5$  *Eimeria necatrix* oocysts and killed 5 days PI.

24, 48, 72, and 96 hr PI. The 5 chickens in group 2 served as control birds. All chickens were killed at 5 days PI, their intestinal lesions scored, and a piece from area B (as defined earlier) of each intestine fixed for light microscopy.

In experiment 2, 12 chickens were each inoculated with  $1.4 \times 10^5$  sporulated oocysts and divided into 3 equal groups. Chickens in groups 1 and 2 served as irritant-injected birds and were each injected i.p. with 10 ml of proteose peptone at 0 and 12 hr PI, respectively. Birds in group 3 were the control birds. All chickens were killed 5 days PI and processed as described for experiment 1.

In the third experiment, 20 chickens were each inoculated with  $1.5 \times 10^5$  sporulated oocysts and divided into 4 equal groups. Chickens in groups 1, 2, and 3 received 10 ml of the irritants, starch, thioglycollate broth, and Sephadex, respectively, as an i.p. injection, at the time of oocyst inoculation. Group 4 served as control birds. All chickens were killed 5 days PI and the intestines processed as described in experiment 1.

**Development of meronts:** The results of the previous experiment showed that irritant-injected birds had lower lesion scores at 5 days PI and preliminary histological examination of their intestines indicated that the second-generation meronts were at the 72-hr rather than the 120-hr stage of development. To explore this finding further the following experiment was performed. Four groups of 5 chickens each were inoculated with  $1 \times 10^5$  sporulated oocysts. Chickens in groups 1, 2, and 3 served as irritant-injected birds and received 12 ml proteose peptone at 0, 24, and 48 hr PI, respectively. Those in group 4 served as control birds. All chickens were killed 72 hr PI and the intestines fixed and processed for light microscopy as described above. From each intestine a total of 300 crypts in 3 histological sections of area B were analyzed for the presence of early second-generation meronts.

**Sporozoite transport:** The first experiment was designed to investigate the migration of sporozoites from the surface to the crypt epithelium and the second to

determine whether sporozoites migrated extraintestinally. In both experiments the effects of the irritant, proteose peptone, injected i.p. at the time of oocyst inoculation were investigated. The presence of viable sporozoites in various tissues was determined by the ability of these tissues to induce infections in coccidia-free chickens.

In the first experiment, 24 birds were each injected i.p. with 12 ml of proteose peptone at the time of oocyst inoculation (irritant-injected) and 18 served as control birds. All birds, except those killed at 3 hr PI, were inoculated with  $5 \times 10^6$  sporulated oocysts. The latter birds were given  $1.2 \times 10^7$  oocysts. Four irritant-injected and 3 control birds were killed at 3, 6, 12, 18, 24, and 48 hr PI. A piece from area B of each intestine was processed for electron microscopy and the rest of the intestine was placed in Bouin's fixative and processed for the counting of sporozoites as described earlier. The number of parasites in 300 crypt-villus units, and their nature and location were analyzed for each intestine.

In the second set, 8 donor chickens were each inoculated with  $10 \times 10^6$  sporulated oocysts and divided into 2 groups. The 4 chickens in group 1 (irritant-injected) received 10 ml of proteose peptone intraperitoneally at the time of oocyst inoculation and the 4 in group 2 served as control birds. Two donor birds, 1 from each group, were killed at 12, 24, 36, and 48 hr PI. From each donor, blood, peritoneal washings, gut, liver, spleen, and kidneys were fed to 6 different recipient birds as described earlier. Recipient birds were starved for 16 hr and were each given 1 g of an alkali powder (calcium carbonate 40%, magnesium trisilicate 17%, and colloidal kaolin 43%) in 1.5 ml of water orally via the crop 10 min prior to the inoculation of tissues. The alkali was given to neutralize the gastric acidity that might otherwise harm or even lyse the sporozoites (Horton-Smith and Long, 1956). The birds were each housed in a separate cage, allowed food and water *ad libitum*, and all feces passed during each 24-hr period beginning on day 6 after the inoculation of donor tis-



TABLE I. *Effect of intraperitoneal irritant injections administered at various time intervals postinoculation on the development of Eimeria necatrix in chickens.*

	Intraperitoneal injection of 10 ml proteose peptone given at various hours PI			
	0	24	48	Control
Mean numbers of infected crypts $\pm$ 1 SD*	0.48 $\pm$ 1.07	13.9 $\pm$ 9.46	19.77 $\pm$ 6.0	14.89 $\pm$ 6.01

\* Crypts infected with early second-generation meronts per 300 crypts per bird. All birds inoculated with  $1.4 \times 10^5$  oocysts and killed at 72 hr PI.

sues were collected. A sentinel recipient, fed the alkali powder only, was included for each time interval to monitor extraneous infection. The total number of oocysts in each 24-hr fecal collection was determined by the method of Long and Rowell (1958). This experiment was replicated 3 times.

**Effect of irritants on oocyst production:** Because irritants injected intraperitoneally delayed the maturation of second-generation meronts, the following experiments were performed to determine whether oocyst production was similarly affected by the irritants. Three experiments with oocyst doses of  $1 \times 10^3$ ,  $5 \times 10^3$ , and  $2.5 \times 10^4$  were performed. In the first, 10 birds were each inoculated with  $1 \times 10^3$  oocysts and 5 of these given 15 ml of the irritant proteose i.p. at the time of oocyst inoculation. The other 5 served as control birds. In the second experiment, 8 birds were each inoculated with  $5 \times 10^3$  oocysts and 4 of them given 10 ml of the irritant proteose peptone i.p. at the time of oocyst inoculation. In the third experiment, 20 birds were each inoculated with  $2.5 \times 10^4$  oocysts and 10 were injected i.p. with 12 ml of the irritant proteose peptone at the time of oocyst inoculation. The other 10 served as control birds. In all experiments the birds were caged individually and the feces passed during each 24-hr period beginning at 6 days PI were collected separately. The total number of oocysts in each 24-hr collection was determined as described above. Total oocyst production for a group is expressed as the mean number of oocysts produced per bird in that group for the period 6–15 days PI.

## RESULTS

In initial experiments irritant-injected birds received i.p. injections of proteose peptone at the time of oocyst inoculation and at 24, 48, 72, and 96 hr PI. However, the results of these experi-

ments did not differ from those in which the proteose peptone was injected only at the time of oocyst inoculation. Therefore, in all subsequent experiments irritant-injected birds received only the first i.p. injection of the designated irritant substance.

### Effect of irritants on the development of lesions

Intestinal lesions seen at 5 days PI were less severe in irritant-injected birds receiving proteose peptone than in control chickens (Fig. 1). Mature second-generation meronts were seen in histological sections from the intestines of control bird, whereas only very early, immature meronts at the 72-hr stage of development were present in the irritant-injected birds. Giving the irritant as a single i.p. injection at 0 hr PI or at 12 hr PI did not change the effects of the irritant on the severity of the lesions (Fig. 1).

Similar results were obtained with several other irritants given i.p. to chickens at the time of oocyst inoculation. At 5 days PI, irritant-injected birds given thioglycollate broth, starch, and Sephadex had mean lesion scores of 1, 1.6, and 2.8, respectively, whereas control birds had a mean lesion score of 5.

### Development of meronts

The mean numbers of crypts infected with early second-generation meronts in irritant-injected

TABLE II. *The distribution of Eimeria necatrix in the crypts of chicken small intestine at 12, 24, and 48 hr postinoculation in birds injected with an intraperitoneal irritant at the time of oocyst inoculation (I) and in control (C) birds.*

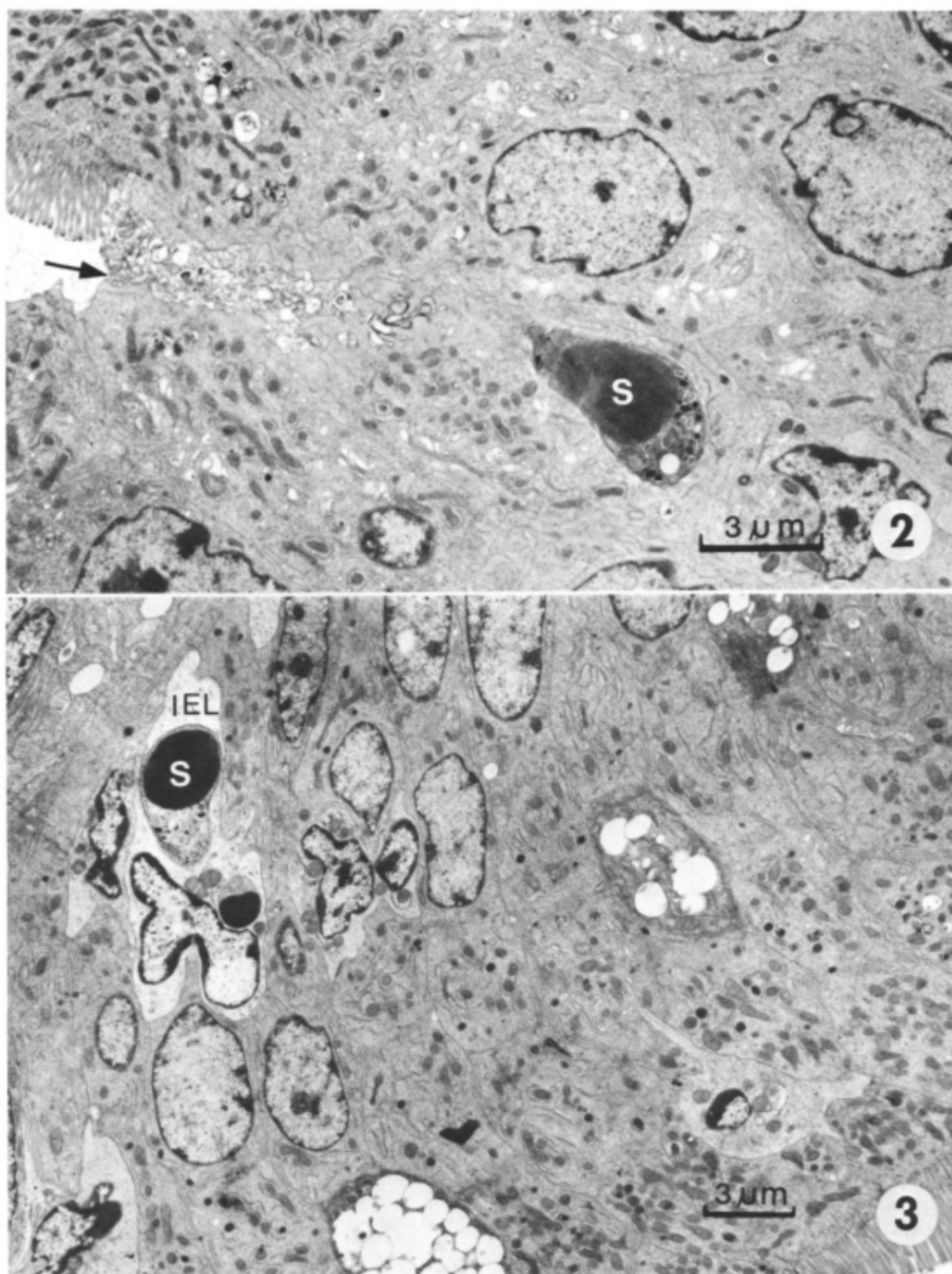
Numbers of parasites in crypts	Hours postinoculation*					
	12		24		48	
	I	C	I	C	I	C
Sporozoites in IEL†	0	4.4 $\pm$ 4.1‡	1.6 $\pm$ 1.6	19.0 $\pm$ 4.0	8.0 $\pm$ 6.5	19.2 $\pm$ 9.4
Sporozoites in epithelial cells	0	0	1.1 $\pm$ 1.0	15.6 $\pm$ 4.1	9.8 $\pm$ 9.9	18.6 $\pm$ 7.7
Developing trophozoites in epithelial cells	0	0	0	0	8.8 $\pm$ 8.7	73.6 $\pm$ 45

\* Birds inoculated with  $5 \times 10^6$  oocysts. Four i.p.-injected and 3 control birds killed at each time interval.

† IEL = intraepithelial lymphocyte.

‡ Mean  $\pm$  1 SD of parasites in 300 crypt-villus units per chicken.





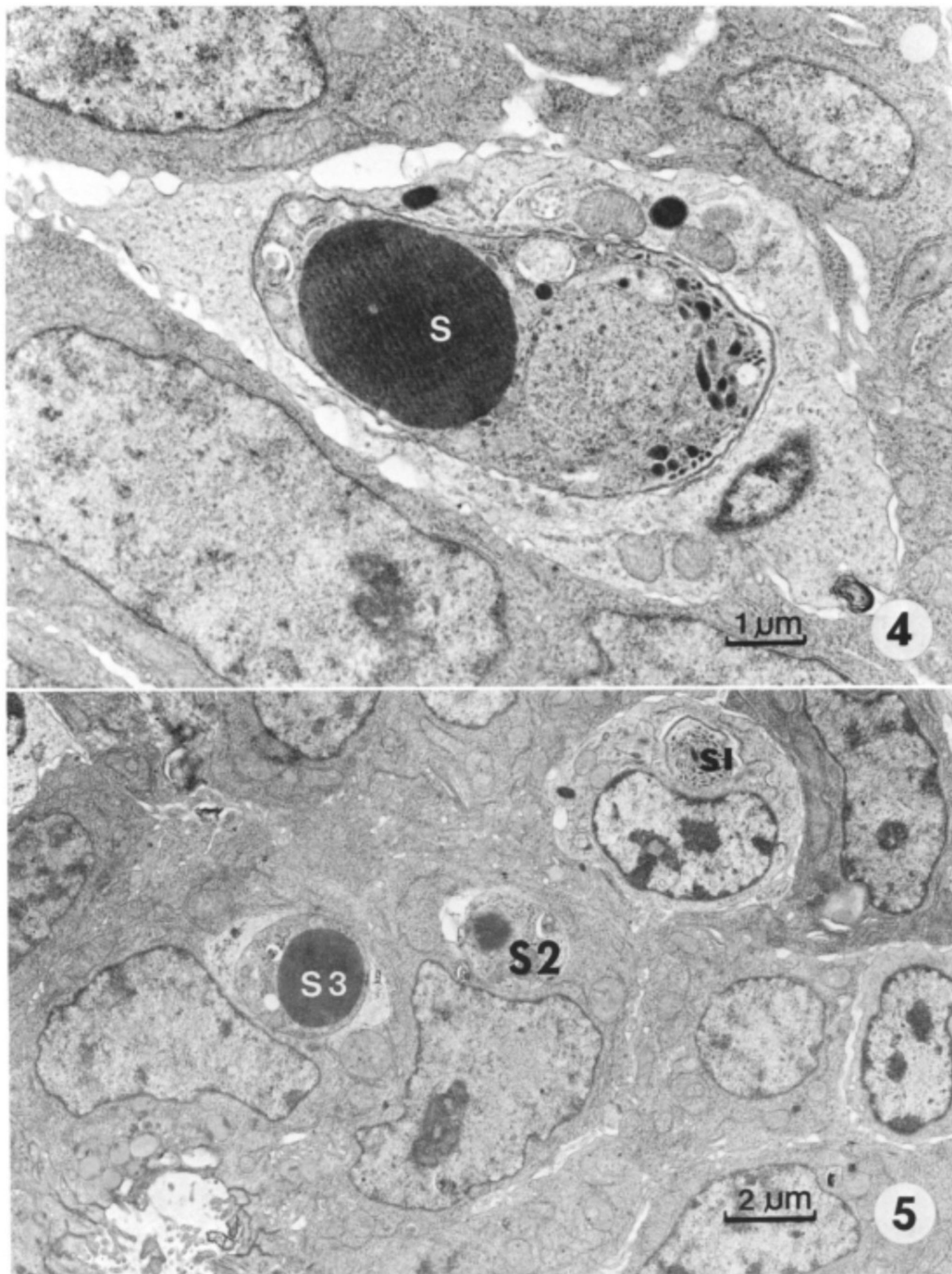
FIGURES 2, 3. Electron micrographs of the small intestine of chickens infected with *Eimeria necatrix*. 2. Sporozoite (S) in villous epithelial cell at 3 hr PI. Disruption of microvilli indicated by arrow. 3. Sporozoite (S) in intraepithelial lymphocyte (IEL) between villous epithelial cells seen at 6 hr PI. Note pale cytoplasm and irregular contours of IEL.

birds and control birds killed 72 hr PI are shown in Table I. The number of infected crypts in birds given the irritant at the time of oocyst inoculation (group 1) was significantly less ( $P < 0.01$ ) than in the control birds (group 4). When the irritant injection was delayed for 24 or more hours

after the inoculation of oocysts (groups 2 and 3) there was no significant reduction in the numbers of infected crypts compared to control birds.

*Sporozoite transport from villus to crypt:* Sporozoites were seen in villous epithelial cells as early as 3 hr PI (Fig. 2) and in mononuclear cells





FIGURES 4, 5. Electron micrographs of small intestine of chickens infected with *Eimeria necatrix*. **4.** Sporozoite (S) within intraepithelial lymphocyte between crypt epithelial cells at 18 hr PI. Note cytoplasmic granules of IEL, parasitophorous vacuole around sporozoite, and mitochondria of the lymphocyte close to the membrane of the parasitophorous vacuole. **5.** Three sporozoites in crypt at 24 hr PI. One sporozoite (S1) is within an intraepithelial lymphocyte, the other 2 (S2, S3) are within crypt epithelial cells.

within the epithelium above the basal lamina and between villous epithelial cells at 6 hr PI (Fig. 3) in both irritant-injected and control birds. At 12 hr PI they were in similar cells in the lamina propria and a few were in the crypts in

control birds. From 18 hr PI onwards, sporozoites were seen in mononuclear cells between crypt epithelial cells and within crypt epithelial cells in control birds, but very infrequently in irritant-injected birds (Figs. 4, 5). Significantly



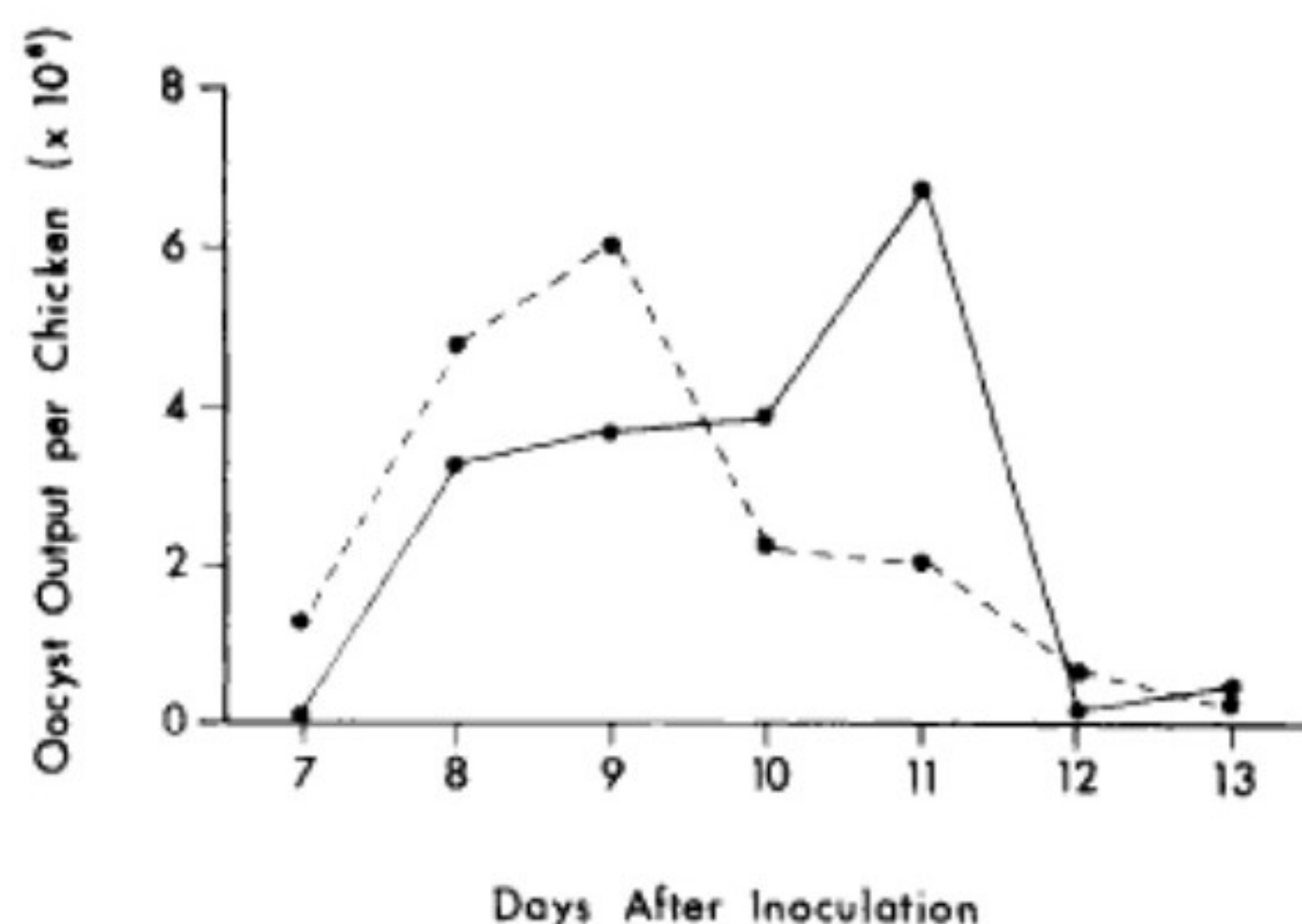


FIGURE 6. Mean daily oocyst output per chicken in chickens given an intraperitoneal injection of proteose peptone at the time of oocyst inoculation (●—●) compared to that of controls (●---●). Each chicken was inoculated with  $5 \times 10^5$  *Eimeria necatrix* oocysts.

fewer sporozoites were at the crypt by 24 hr PI in irritant-injected birds compared to control birds (Table II).

Ultrastructurally, the mononuclear cells within which sporozoites were found were granulated and resembled lymphocytes (IEL; Figs. 3, 4). The granules are bounded by a single unit membrane, the cytoplasm is pale, and contains sparse cytoplasmic organelles, e.g., small round mitochondria and the nucleus and the cell itself have very irregular contours (Figs. 3, 4). Sporozoites were not seen in any other type of leukocyte nor were sporozoites seen free in the lamina propria. Sporozoites within host cells were always seen bounded by a parasitophorous vacuole. Further morphological development of the sporozoites was observed only within crypt epithelial cells.

*Parasites found extraintestinally:* Total numbers of oocysts found in the fecal samples of recipient birds 6–11 days after the inoculation of

tissues taken from donor birds at various time intervals PI are shown in Table III. Infection was transferable by gut scrapings, liver, and spleen from irritant-injected birds and control birds at all time intervals, and by blood and kidney homogenates from these birds at a few time intervals. A few oocysts were passed by the recipients of peritoneal wash taken 12 hr PI from the irritant-injected birds. At 12 hr PI, liver and spleen homogenates from control birds produced more oocysts in recipients than those from irritant-injected birds, while at the 36-hr interval, these tissues from irritant-injected birds produced 3 times as many oocysts as those from the control birds. In all transfers, the prepatent period was normal and no oocysts were detected in the sentinel recipients that were housed in the same room as the experimental recipients.

*Production of oocysts:* Peak oocyst production was delayed by approximately 48 hr in irritant-injected as compared to control birds (Fig. 6). However, the total numbers of oocysts produced by irritant-injected birds in each of the 3 experiments were not significantly different from those produced by the control birds. In experiments 1, 2, and 3, the irritant-injected birds produced  $1 \times 10^7$ ,  $1.9 \times 10^7$ , and  $2 \times 10^7$  and the control birds produced  $2 \times 10^7$ ,  $1.8 \times 10^7$ , and  $2.6 \times 10^7$  oocysts per bird, respectively.

## DISCUSSION

Our results confirm the observations of Van Doorninck and Becker (1957) that *E. necatrix* sporozoites first enter villous epithelial cells of the chicken small intestine and are transported by mononuclear cells to the crypt epithelium where they develop into first-generation meronts. However, our ultrastructural studies indicate that the host cell transporting the sporozoite

TABLE III. Output of oocysts of *Eimeria necatrix* in feces of recipient birds 6–11 days after inoculation with tissues obtained from infected donors.

Tissue inoculated to recipients	Hours postinoculation of donors from which tissues were transferred to recipients							
	12		24		36		48	
	I*	C†	I	C	I	C	I	C
Blood	0.03‡	1.10	0.14	0.06	0.04	0.00	0.00	0.00
Peritoneal wash	0.05	0.00	0.00	0.00	0.00	0.00	0.00	0.00
Spleen	0.15	0.42	0.10	0.50	0.74	0.21	Not done	
Kidneys	0.00	0.06	0.02	0.07	0.02	0.00	0.00	0.00
Liver	0.14	0.76	2.11	0.52	1.47	0.76	0.73	0.65
Mucosa	2.97	1.47	5.29	Died	Died	5.35	Died	12.73

\* I = donors each given an intraperitoneal injection of 10 ml proteose peptone at time of oocyst inoculation.

† C = control donors.

‡ Number of oocysts ( $\times 10^6$ ) in feces of recipients, representing the means of 3 replicate experiments.



is a granulated intraepithelial mononuclear cell, morphologically resembling the intraepithelial lymphocyte described by Lawn and Rose (1982), and not a macrophage, as suggested above. Indirect evidence against sporozoite transport by macrophages in *E. tenella* has been provided by Lee and Al-Izzi (1981). An intraepithelial lymphocyte has been implicated in the transport of *E. tenella* sporozoites from surface to crypt epithelium in the cecum of the chicken (Lawn and Rose, 1982). The mechanism(s) by which sporozoites enter or leave IEL's is not known, but all sporozoites seen by us within these cells were bounded by a parasitophorous vacuole suggesting some form of internalization of the sporozoite.

Human intraepithelial lymphocytes were reviewed by Dobbins (1986) and rodent IEL's by Ernst et al. (1985). In the rodent, the granulated intraepithelial mononuclear cell morphologically recognized as a globule leukocyte is termed an intraepithelial mast cell and the large granular lymphocyte type cell and the smaller nongranulated lymphocytes are all termed intraepithelial lymphocytes and divided into 4 subsets on the basis of their surface markers. The avian intraepithelial cells are not as well described or classified. Bjerregaard (1975), in the first comprehensive review of lymphocytes in the chicken intestinal epithelium, classified them into 2 categories, i.e., nongranulated intraepithelial lymphocytes and large lymphocytes with 1–5 granules. The identity of the avian globule leukocyte is in question. Until these cells are better characterized, we will tentatively call the cells that transport *E. necatrix* sporozoites, intraepithelial lymphocytes.

Patent infections were produced in birds that received blood, liver, spleen, and kidneys of donor birds orally inoculated with large numbers of sporulated oocysts indicating that these parasites travel outside the gut mucosa. Whether they do within IEL in which sporozoites are found in the mucosa is not known. We also do not know what proportion of the parasites found in extraintestinal sites return to the crypts to continue their development. However, stimuli outside the intestinal tract, i.e., an irritant such as proteose peptone injected into the peritoneal cavity of chickens at the time of oocyst inoculation can delay sporozoite return to the crypt epithelium.

The intraperitoneal injection of an irritant caused a delay in the time of peak arrival of sporozoites at the crypts by about 24 hr. This

was reflected by a delay in the development of intestinal lesions and in peak oocyst production. However, the similarity in the total numbers of oocysts produced by irritant-injected and control birds indicates that sporozoites are not lost to any significant extent during their travels in irritant-injected birds as compared to control birds. Lawn and Rose (1982) found that after the inoculation of very large numbers of *E. tenella* oocysts, only a fraction of the sporozoites that enter the surface epithelium of the cecum reaches the crypts. They suggested that this loss may be caused by the shedding of sporozoites within effete enterocytes or by the destruction of transport cells within the lamina propria, or by the deviation of parasitized IEL into a different pathway of migration. Our results indicate that a proportion of this loss could take place in extraintestinal sites.

Recently, Kogut and Long (1984) showed that homogenates of liver and gut, but not spleen, taken from chickens and turkeys 3 days after they were dosed with a mixture of *Eimeria* species of the chicken were infective to other chickens. Extraintestinal dissemination of the sporozoites of *E. stiedai* shortly after oral inoculation of oocysts has been reported by several workers (Horton, 1967; Dürr, 1972). Similarly, our results indicate that extraintestinal migration by sporozoites of *Eimeria* species may occur more frequently than was previously believed.

Among other questions, one can ask: is the normal fate of an IEL altered by the invasion of a sporozoite; what mechanism(s) represses parasitic development while the parasite is within the IEL; and is the contact of an IEL with a crypt epithelial cell fortuitous? It is not known whether sporozoites exert any influence on the migration pattern of IEL, a cell whose route of migration is not known with certainty at the present time (Ernst et al., 1985). We do know, however, that an irritant such as proteose peptone injected intraperitoneally into chickens at the time of oocyst inoculation or shortly thereafter overrides any influence the sporozoites might have on IEL traffic and delays the arrival of infected IEL at the crypts. Leukocytes are known to migrate into the peritoneal cavity soon after an irritating substance is injected i.p. Such methods have been used to obtain large numbers of blood leukocytes (Mahmoud et al., 1975) and macrophages (Long and Rose, 1976; Sabet et al., 1977; Trifonov et al., 1977) from the peritoneal exudate of chickens and other animals. Cells harvested from the per-



itoneal cavity of irritant-injected birds 12 hr PI were able to induce infections when given orally to coccidia-free chickens, indicating that infected IEL are also attracted to this site. Development of the first-generation meront of *E. dispersa* of the turkey takes place in IEL within the villous epithelium (Millard and Lawn, 1982) and not in the crypt. Whether a similar delay in the development of this species would occur as a result of an intraperitoneally injected irritant is not known and would be worthwhile investigating. Finally, similar studies on other species of *Eimeria* that are reported to be transported by leukocytes is warranted. If these infected leukocytes are also found to be attracted by irritating substances in the peritoneal cavity, concurrent bacterial infections may have similar effects on the life cycles of these *Eimeria* spp. and delay the development of lesions and peak oocyst production. These possibilities should be kept in mind during investigations of the life cycles of *Eimeria* spp.

#### ACKNOWLEDGMENTS

We are grateful for the skilled assistance of Anne Sylvestre, Orvar Remmler, Carol Skene, and Ted Eaton. Many thanks to Susan Slack for help with the figures and the typing. This work was supported by a grant to MAF from the Natural Sciences and Engineering Research Council of Canada and by the Ontario Ministry of Agriculture and Food. Part of the work reported here is from a thesis submitted by M. A. Al-Attar to the University of Guelph in partial fulfillment of the Ph.D. degree.

#### LITERATURE CITED

- BJERREGAARD, P. 1975. Lymphoid cells in chicken intestinal epithelium. *Cell and Tissue Research* **161**: 485-495.
- CHALLEY, J. R., AND W. C. BURNS. 1959. The invasion of cecal mucosa by *Eimeria tenella* sporozoites and their transport by macrophages. *Journal of Parasitology* **6**: 238-241.
- DOBBINS, III, W. O. 1986. Human intraepithelial lymphocytes. *Gut* **27**: 972-985.
- DORAN, D. J. 1966. The migration of *Eimeria acervulina* sporozoites to the duodenal glands of Lieberkuhn. *Journal of Protozoology* **13**: 27-33.
- DÜRR, V. 1972. Life cycle of *Eimeria stiedae*. *Acta Veterinaria, Academiae Scientiarum Hungaricae* **22**: 101-103.
- ERNST, P. B., D. A. BEFUS, AND J. BIENENSTOCK. 1985. Leukocytes in the intestinal epithelium: An unusual immunological compartment. *Immunology Today* **6**: 50-55.
- HORTON, R. J. 1967. The route of migration of *Eimeria stiedae* (Lindemann, 1865) sporozoites between the duodenum and bile ducts of the rabbit. *Parasitology* **57**: 9-17.
- HORTON-SMITH, C., AND P. L. LONG. 1956. Studies in histomoniasis. 1. The infection of chickens (*Gallus gallus*) with histomonad suspensions. *Parasitology* **46**: 79-90.
- KOGUT, M. H., AND P. L. LONG. 1984. Extraintestinal sporozoites of chicken *Eimeria* in chicken and turkeys. *Zeitschrift für Parasitenkunde* **70**: 287-295.
- LAWN, A. M., AND M. E. ROSE. 1982. Mucosal transport of *Eimeria tenella* in the cecum of the chicken. *Journal of Parasitology* **68**: 1117-1123.
- LEE, E.-H., AND S. A. AL-IZZU. 1981. Effect of selective killing of macrophages in the peritoneal cavity by carrageenan on normal infection of *Eimeria tenella* in chickens. *Avian Diseases* **25**: 503-512.
- LONG, P. L., AND M. E. ROSE. 1976. Growth of *Eimeria tenella* in vitro in macrophages from chicken peritoneal exudates. *Zeitschrift für Parasitenkunde* **48**: 291-294.
- , AND J. G. ROWELL. 1958. Counting oocysts of chicken coccidia. *Laboratory Practice* **7**: 515-518, 534.
- MAHMOUD, A. A. F., K. S. WARREN, AND R. C. GRAHAM, JR. 1975. Anti-eosinophil serum and the kinetics of eosinophilia in *Schistosoma mansoni*. *Journal of Experimental Medicine* **142**: 560-574.
- MILLARD, B. J., AND A. M. LAWN. 1982. Parasite-host relationships during the development of *Eimeria dispersa* Tyzzer, 1929, in the turkey (*Meleagris gallopavo gallopavo*) with a description of intestinal intraepithelial leukocytes. *Parasitology* **84**: 13-20.
- PATILLO, W. H. 1959. Invasion of the cecal mucosa of the chicken by sporozoites of *Eimeria tenella*. *Journal of Parasitology* **45**: 253-258.
- PEIRCE, M. A. 1980. A simple staining technique to demonstrate the sporozoite refractile globule in coccidial parasites. *Parasitology* **80**: 551-554.
- SABET, T., W. H. HSIA, M. STANISZ, A. EL-DOMEIRI, AND P. V. ALLEN. 1977. A simple method for obtaining peritoneal macrophages from chickens. *Journal of Immunological Methods* **14**: 103-110.
- STOCKDALE, P. G. H., AND M. A. FERNANDO. 1975. The development of the lesions caused by second generation schizonts of *Eimeria necatrix*. *Research in Veterinary Science* **19**: 204-208.
- TRIFONOV, S., N. SOTIROV, AND A. FILICHEV. 1977. In vitro migration of peritoneal and spleen cells and its inhibition in some avian species. *Cellular Immunology* **32**: 361-369.
- VAN DOORNINCK, W. M., AND E. R. BECKER. 1957. Transport of sporozoites of *Eimeria necatrix* in macrophages. *Journal of Parasitology* **43**: 40-44.