4. Titration of rabbit anti-chicken heterophil sera

Anti-heterophil serum was titrated against chicken red blood cells. A hemagglutination titre of 1/8 was obtained with the anti-heterophil serum. No hemagglutination activity was demonstrated at 1/2 dilution in the normal rabbit serum. This hemagglutination activity ws removed completely by absorption of the serum with chicken red blood cells.

Cytotoxic activity of the anti-heterophil serum was evident at 1/4, 1/8 and 1/16 dilutions. In these dilutions, most heterophils were lysed or unable to exclude trypan blue. On the other hand, at higher serum dilutions heterophil lysis was not prominent and trypan blue exclusion by heterophils was comparable in both normal rabbit serum and the anti-heterophil serum. However, more dead heterophils was observed in the 1/32 and 1/64 dilutions of the anti-heterophil serum than in the normal rabbit serum. The cytotoxicity assay was performed only with the anti-heterophil serum which was obtained from the first immunization trial. Due to difficulty in reading due to spontaneous death of heterophils after the incubation period, this test was abandoned.

Using the agglutination test, it was possible to titrate the anti-heterophil sera. Serum obtained from the first trial of rabbit immunization had a titre of 1/128. On the other hand, serum titers of individual rabbits which were used in the second immunization trial ranged from 1/256 to 1/512. Since these titers were comparable, the sera were pooled. The titre of the pooled anti-heterophil serum was reduced dramatically after absorption with chicken red blood cells, peritoneal macrophages, lymphocytes and the polymerized normal chicken plasma proteins. The titre after absorption was 1/64.

The anti-heterophil serum was also tested, before and after absorption, in the DID test against tissue antigens prepared from heterophils, macrophages, liver, thymus, bursa and normal chicken serum and plasma. Lines of precipitation were detected with all antigens used against absorbed and unabsorbed anti-heterophil serum (Fig. 2-37).

5. In vivo use of anti-heterophil sera

No decrease in circulating heterophils was obtained after injection of absorbed anti-heterophil serum prepared by the first schedule of immunization. On the contrary, an increase in the number of heterophils as well as total leucocytes were obtained after injection of anti-heterophil and normal rabbit sera during the first three experiments. Heterophil numbers, after injection of anti-heterophil and normal rabbit serum (Experiment 1) are shown in Fig. 2-38).

Although the titre of the second batch of anti-heterophil serum was higher, no decrease in the number of circulating heterophils was obtained in any of the experiments performed. The injection of anti-heterophil serum, whether absorbed or not was followed shortly by an increase in heterophil numbers regardless of the route of administration. This was followed by a decrease to about the pre-injection level (Fig. 2-39).

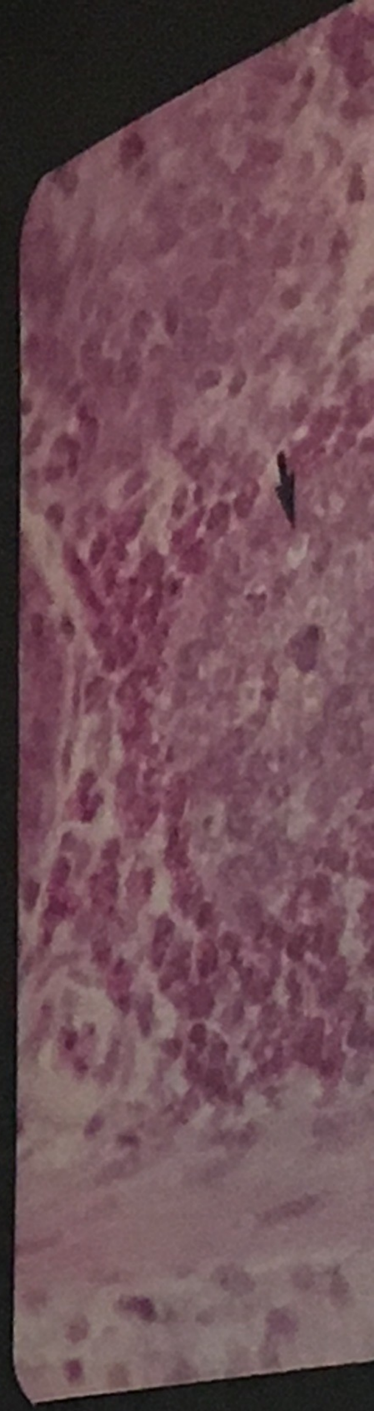

Figure 2-1. Section of chicken intestine 69 hours after infection with E. necatrix. Note the absence of any inflammatory reaction around first generation schizont (large arrow) compared to the intensity of heterophil infiltration (H) around early second generation schizonts (small arrow). H & E stain. (x 400)

Figure 2-2. Similar to Fig. 2-1 showing heterophil infiltration on both sides of infected crypt epithelial cells harbouring early second generation schizonts. Note that no such infiltration is seen around uninfected crypt epithelial cells at the top of the crypt (arrow). H & E stain. (x 400)

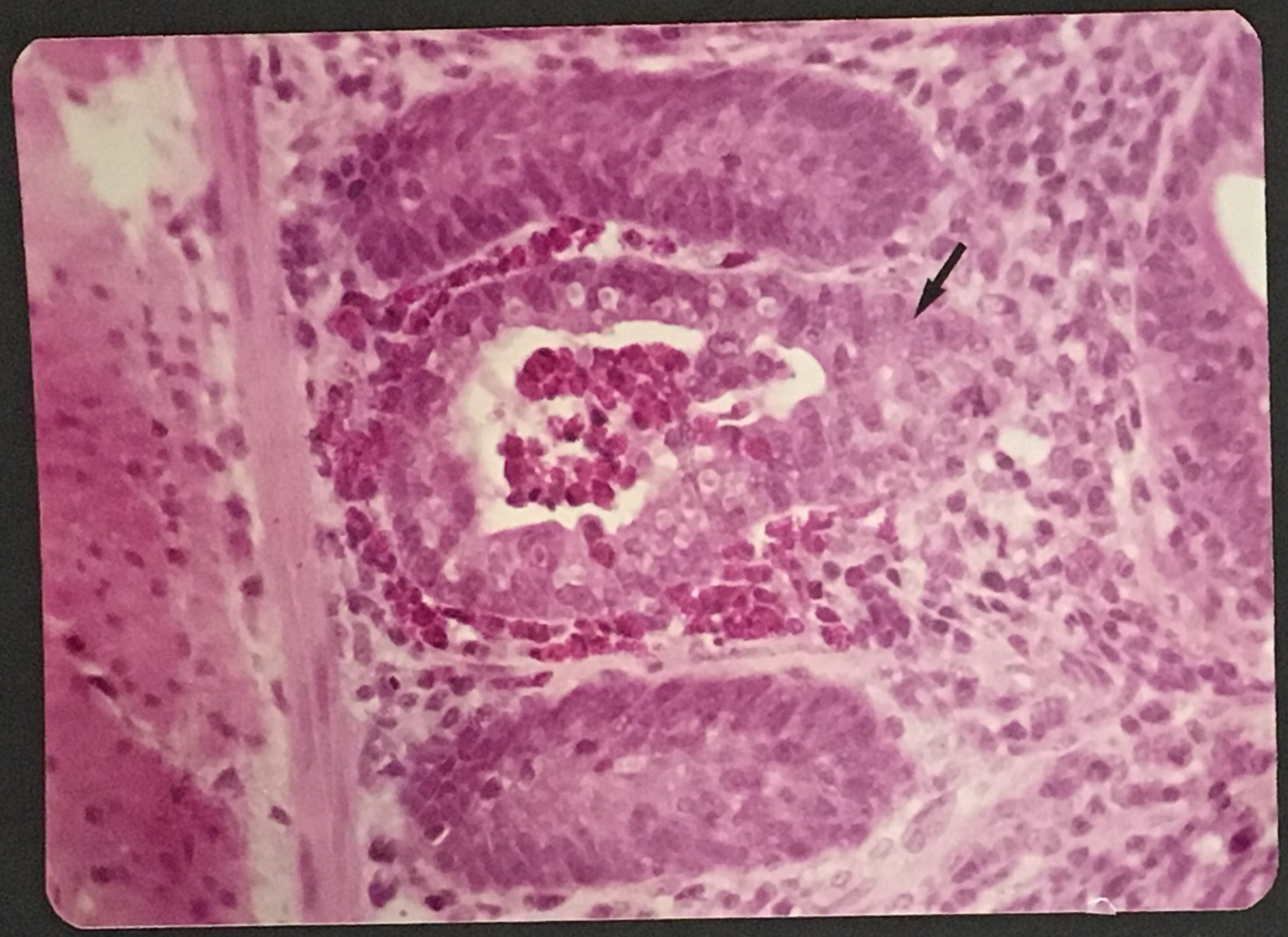

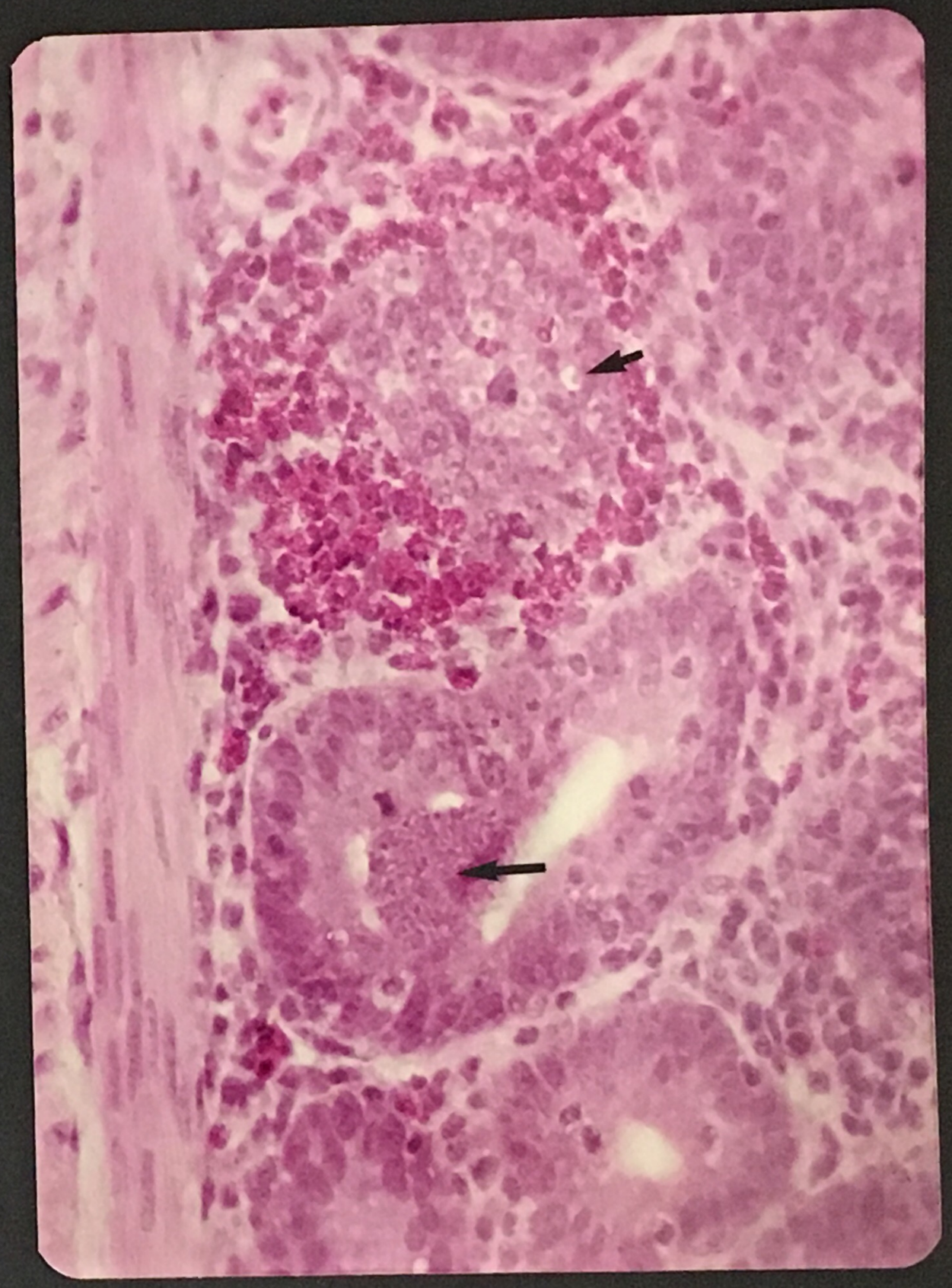

Figures 2-3, 2-4, 2-9, 2-10, 2-11, 2-13, 2-14 and 2-15.

Electron micrographs of early and mature second generation schizonts of Eimeria necatrix. Abbreviations: second generation merozoite, MZ; uninfected crypt epithelial cell, CE; crypt lumen, CL; microvilli, MV; goblet cell, GC; host cell nucleus, HN; host cell cytoplasm, HC; parasitophorous vacuole, PV; basement membrane, BM; early second generation schizont, SGS; desmosome, DS; vesicle, V; pseudopods, PS; phagosome, P; heterophil, H.

Figure 2-3. Heterophil infiltration around and between infected crypt epithelial cells harboring early second generation schizonts (70 hours post infection). Some heterophils can also be seen in the crypt lumen. (x 7200).

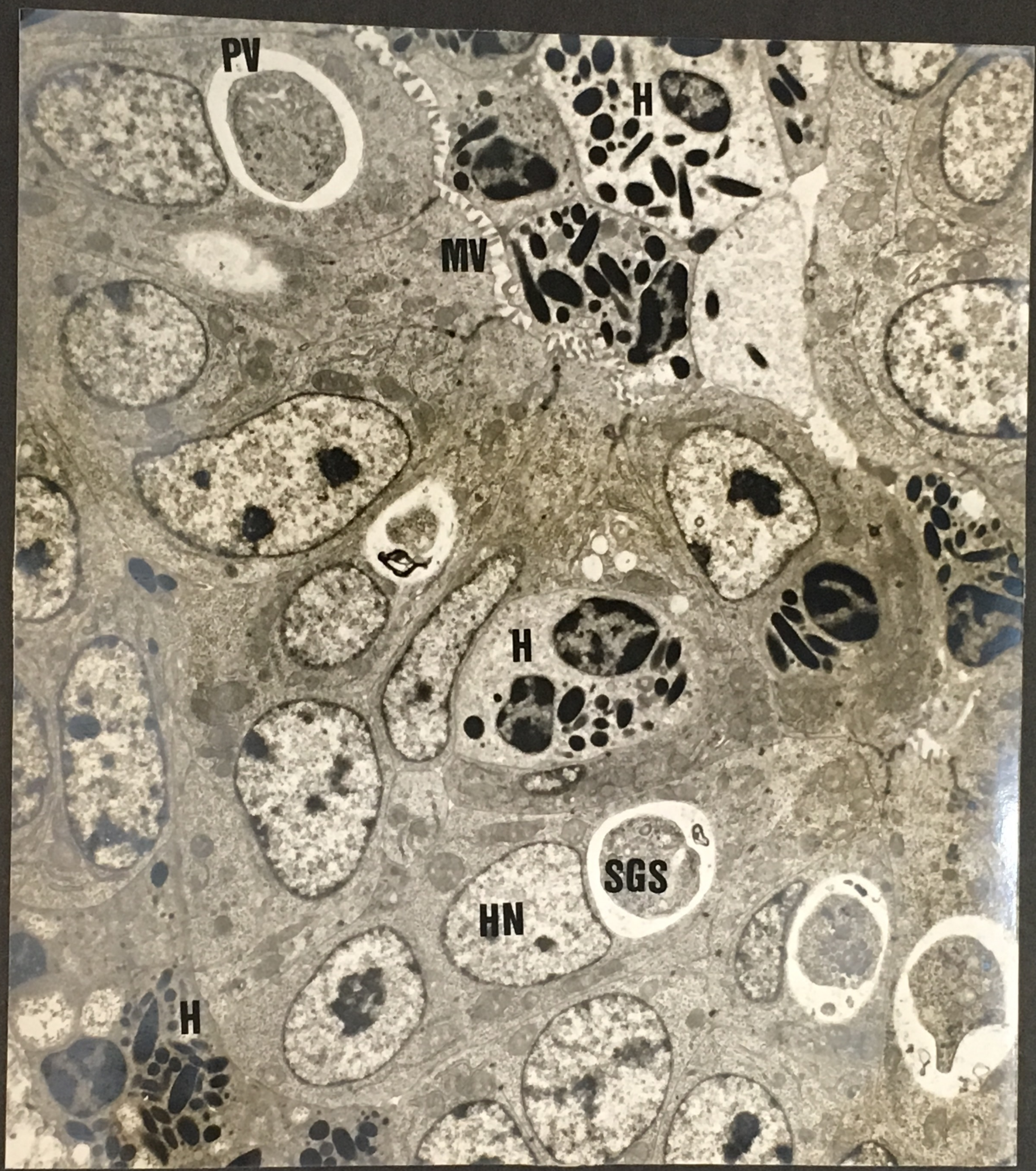
PV
H
MV
H
SGS
HN
H

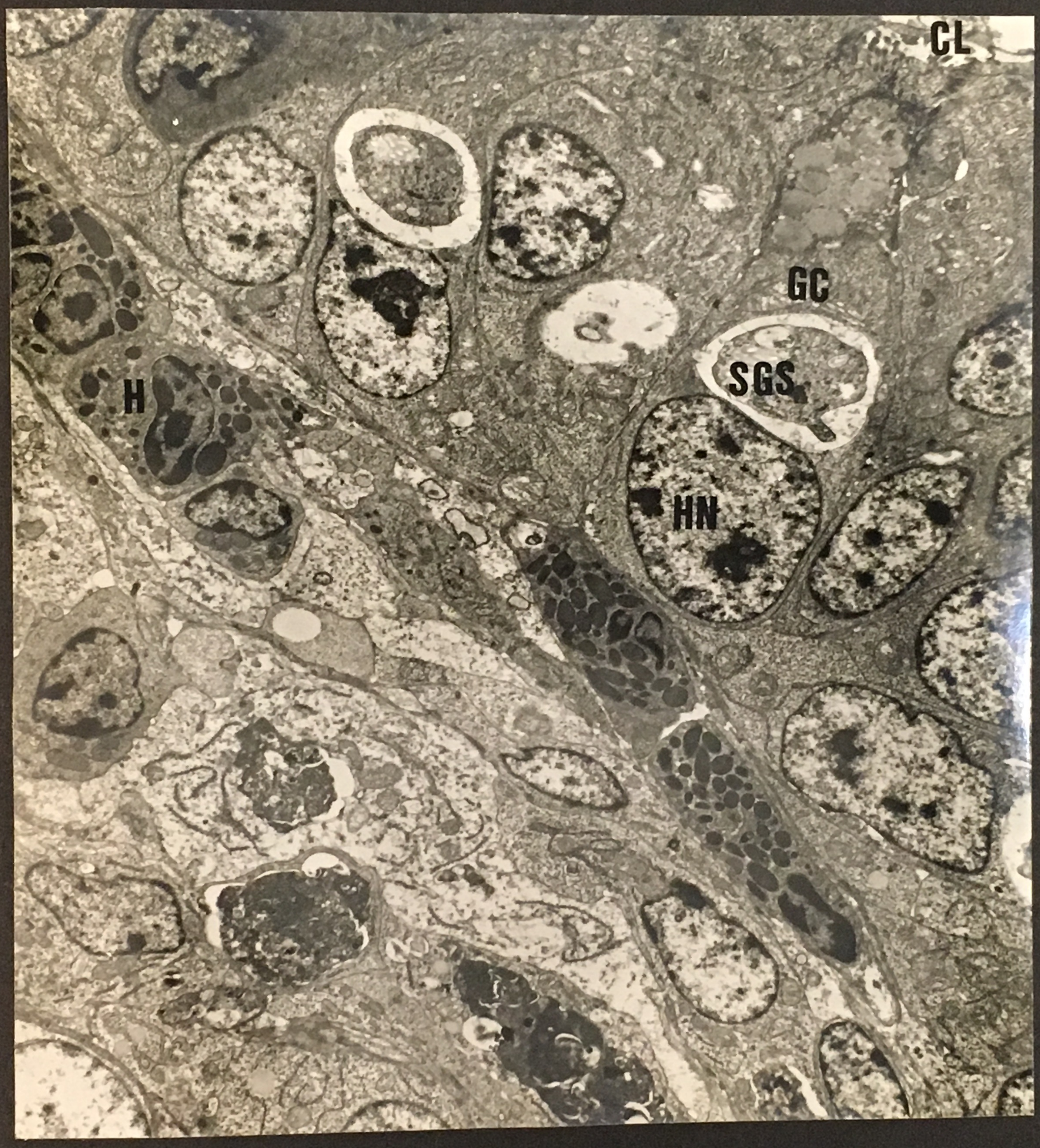
CL
GC
SGS
H
HN

Figure 2-5. Section of infected intestine taken at 69 hours post infection showing different stages of heterophil infiltration. Intact heterophils can be seen around an infected crypt (arrow), degenerated heterophils can be seen in the other infected crypt (D). On the left of the picture many infected cells can be seen in the lamina propria but with no heterophil infiltration in this area. Dilated blood vessels (B) can be seen around crypts. Giemsa stain. (x 400)

Figure 2-6. Intestinal section taken at 69 hours post infection. Few basophils (arrow) can be seen near an infected crypt and in villar lamina propria. Giemsa stain (x 400).

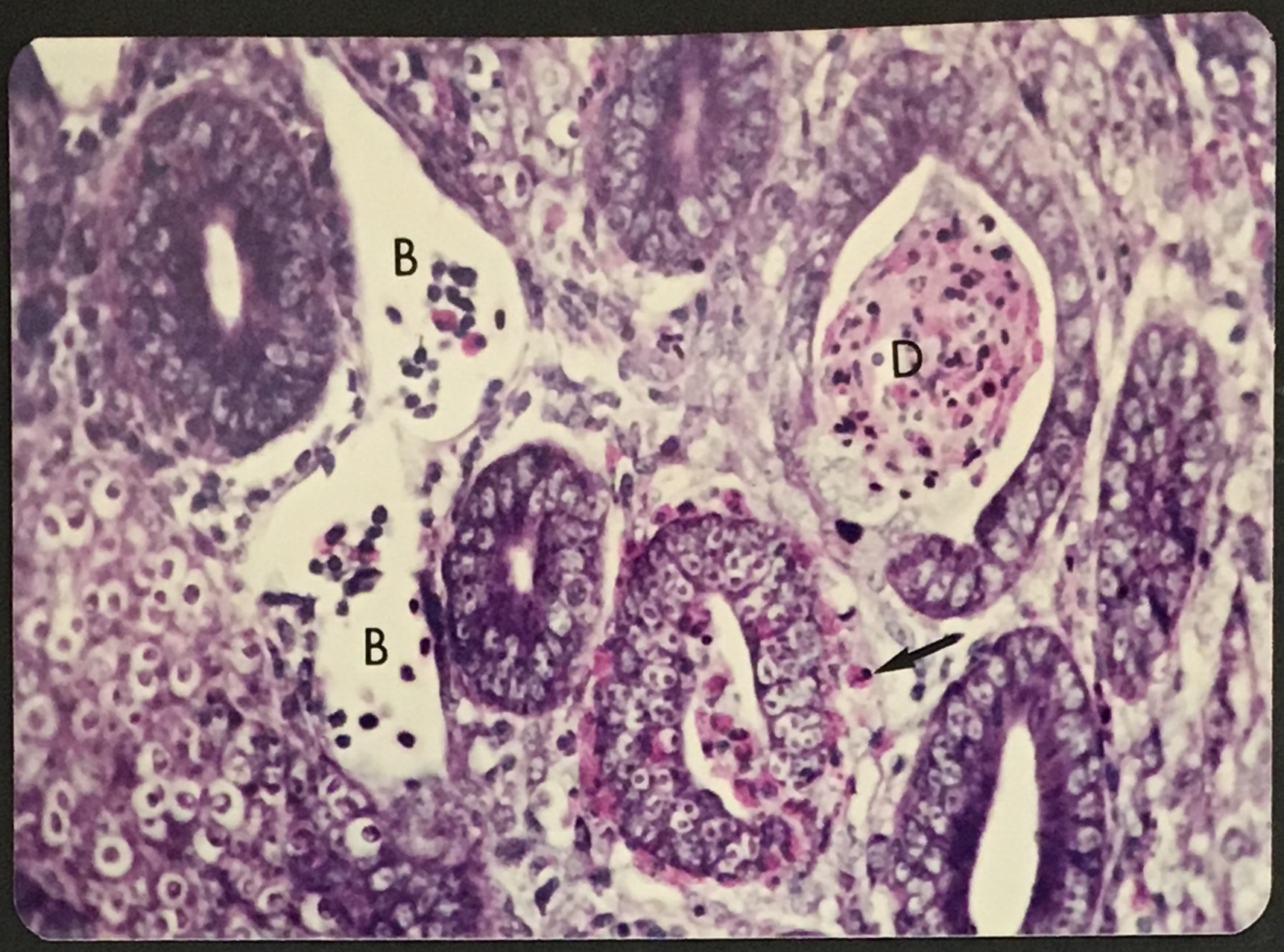
B
B
D

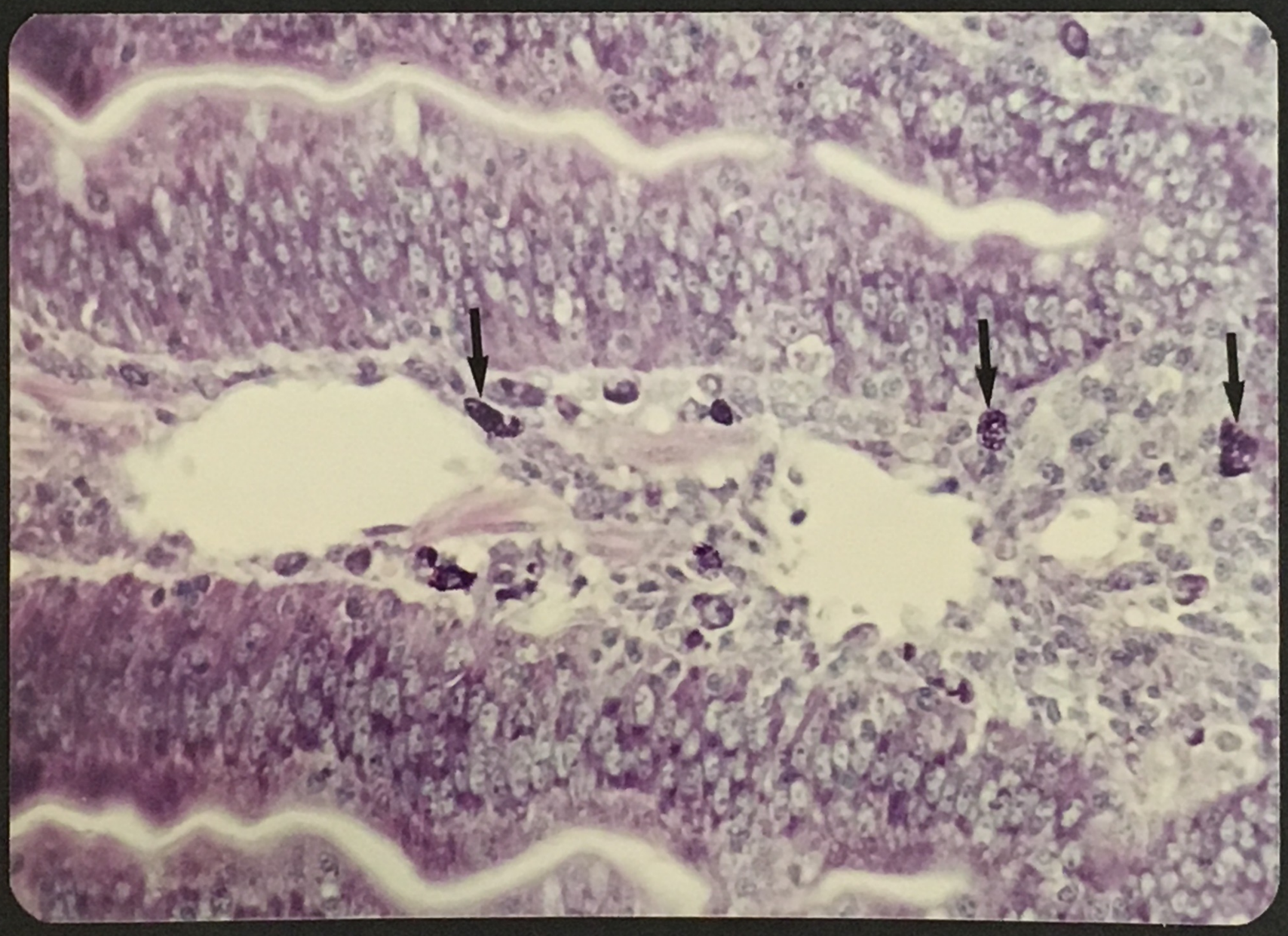

Figure 2-7. Intestinal section showing the close location of blood vessels (B) to crypt epithelial cells in an uninfected area. One micron section stained with methylene blue. (x 400).

Figure 2-8. Intestinal section taken from a chicken 69 hours post infection. Notice the engorgement of a blood vessel (large arrow) with leucocytes near an infected crypt (small arrow). One micron section stained with methylene blue. (x 400)